

Hyperechogenic Colon as a Prenatal Sign of Cystinuria

Fatma Doğa Öcal¹ & Aydan Biri²

¹ University of Health Sciences, Ankara City Hospital, Perinatology Department, Ankara, Türkiye.


² Koru Hospital, Ankara, Türkiye.

ABSTRACT

Cystinuria is a hereditary disease characterized by recurrent urolithiasis in the postpartum period. Early diagnosis is important to prevent kidney failure. During fetal life, a hyperechogenic presentation of the colon in late gestation may be the only indication of cystinuria. Therefore, a hyperechogenic colon in the third trimester should suggest cystinuria among the various diagnoses. We present a case in which cystinuria was suspected prenatally and diagnosed as cystinuria postnatally.

KEYWORDS

Hyperechogenic bowel; colon; cystinuria; prenatal; ultrasound.

 10.62093/e2309

Correspondence

Fatma Doğa Öcal
Ankara Şehir Hastanesi Perinatoloji Kliniği
06800, Çankaya, Ankara, Türkiye
Email: eadoga@yahoo.com

How to cite this article

Öcal FD & Biri A. Hyperechogenic Colon as a Prenatal Sign of Cystinuria. *Adv Res Obstet Gynaecol.* 2023;1(2):e2309. doi: 10.62093/e2309

Copyright license

This is an Open Access article distributed under the terms of the Creative Commons Attribution 4.0 International license (CC BY 4.0).

Introduction

Cystinuria is a genetic disease caused by dysfunction of an amino acid transporter of the proximal renal tubules and small intestinal epithelia with an incidence of 1/7000¹⁻³. Due to insufficient absorption of cystine and other dibasic amino acids (e.g. ornithine, lysine and arginine), there is a risk of recurrent kidney stones and renal failure. During the fetal period, high levels of cystine cause the hyperechoic colonic appearance on ultrasonography, which is a suspected sign for the diagnosis of cystinuria⁴. The normal appearance of the fetal colon on ultrasonography is hypoechoic or isoechoic. Although many pathologic conditions cause a hyperechoic colon, this can be a completely normal finding, especially when discovered in late pregnancy and as an isolated finding.

Diagnosis of cystinuria in the prenatal period is possible by amino acid analysis of the amniotic fluid.

We present a case of prenatally diagnosed cystinuria.

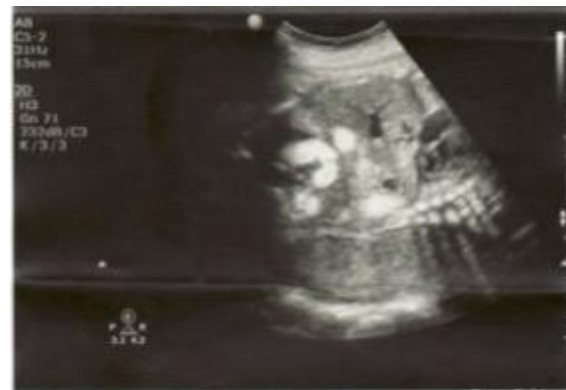Case

A 28-year-old woman, gravida 2 para 1, came to our clinic for a routine check-up when she was 29 weeks pregnant. The ultrasound examination revealed a hyperechogenic lumen of the colon (figure 1). The image was different from the image of hyperechogenic bowel that we normally see. The entire colonic lumen was hyperechogenic. There were no other abnormal ultrasound findings. There were no pathologic conditions in the woman's obstetric, medical, or surgical history, and the family history was unremarkable. The chromosomal screening tests and the detailed ultrasound examination at 22

weeks' gestation were normal. The woman and her husband were examined for a cystic fibrosis mutation, and no pathological findings were detected.

Delivery occurred at 40 weeks, and a 38000 g, 52 cm male newborn was born with an Apgar score of 9/10. After birth, the urine was tested for cystinuria and the diagnosis was confirmed on the fifteenth day after birth.

Figure 1. Ultrasonographic imaging of hyperechogenic colon.



Discussion

An echogenic fetal bowel (EB) is a prenatal ultrasound finding defined as increased echogenicity of the bowel that is as bright as the adjacent bone. This observation applies to 0.2%-1.4% of pregnancies examined during the 20-22 weeks second trimester anatomy scan. This echogenicity may be focal or diffuse, and it may extend along the entire intestinal lumen or involve only the wall (tramline)⁵⁻⁶. The etiologic causes of EB in the second trimester vary. It may be a transient normal finding but may also be due to various pathologic conditions such as chromosomal abnormalities, infections, fetal growth restriction (FGR), cystic fibrosis, anatomic pathologies of the gastrointestinal tract and intraamniotic hemorrhage.

The week of gestation at the time of diagnosis of EB helps to differentiate the etiologic causes. The pathologic mechanism of echogenic imaging depends on the underlying disease. In isolated cases of EB, accumulation of meconium is thought to be the main mechanism. Viral infections appear to cause EB by direct cytotoxic action and ischemia on the developing colon of the fetus, leading to hypoperistalsis, ileus, and eventually intestinal perforation. Cystic fibrosis is a disease in which pancreatic enzymes and intestinal peristalsis are decreased and concentrated meconium causes the echogenic image of the intestine. Pathologies of the gastrointestinal tract such as obstruction lead to an echogenic bowel due to the reduced fluid absorption of the meconium by the obstructed swallowing. During FGR, the distribution of fetal blood changes and allows the vital organs to be exposed, so the blood supply to the intestine decreases and this leads to ischemia in the fetal intestine. EB in the third trimester, especially at 36 weeks, is an expected outcome due to maturation of the fetal intestine and increased absorption of intestinal fluid⁷⁻⁸.

Cystinuria is a genetically inherited disease that primarily affects the proximal tubule of the kidney and the epithelial cells of the intestinal tract. Due to impaired cystine transport, the amount of cystine in fetal urine increases, while absorption in the intestine decreases. The end result of this pathology is an accumulation of cystine in the amniotic fluid. EB due to cystinuria is a late finding, as the physiological maturation of the anal sphincter does not occur until after 22 weeks of gestation. After this time, an increased amount of cystine leads to an echogenic picture that increases over time. In the present case, we detected EB at 29 weeks' gestation, which was

diffuse and resembled the appearance of a barium enema. The accumulation of cystine in the colon is a useful feature to differentiate cystinuria from cystic fibrosis, which usually affects the ileum. The parents looked for cystic fibrosis and the test results were negative. No abnormality was detected on detailed ultrasound examination.

Theoretically, prenatal diagnosis of cystinuria is possible by amino acid analysis, but the only sonographic finding of the disease is a hyperechogenic colon, which occurs late in gestation, and prenatal diagnosis has no bearing on treatment. Therefore, amniocentesis is not recommended. In the early postnatal period, the diagnosis of cystinuria is confirmed by an amino acid analysis of the urine. There is no case of cystinuria diagnosed prenatally⁵⁻⁷. Brasseur-Daudry et al reported 3 cases in which a hyperechogenic colon was visualized prenatally by ultrasound and cystinuria was diagnosed postnatally⁹.

Sometimes the cystine transport matures during this period and leads to a transient form of cystinuria. In our case, the diagnosis of cystinuria was confirmed after birth, and during the follow-up examinations the cystine level in the urine remained elevated.

In conclusion, hyperechogenic bowel, especially found in the third trimester and colonic lumen, is suggestive of cystinuria among other causes. Although prenatal amniocentesis is not recommended, it is necessary for early diagnosis of the disease in the neonatal period.

Conflict of interest

The authors declare that they have no conflicts of interest.

References

1. Eggermann T, Venghaus A, Zerres K. Cystinuria: an inborn cause of urolithiasis. *Orphanet J Rare Dis.* 2012;7:19. Published 2012 Apr 5. doi:[10.1186/1750-1172-7-19](https://doi.org/10.1186/1750-1172-7-19)
2. Dello Strologo L, Rizzoni G. Cystinuria. *Acta Paediatr Suppl.* 2006;95(452):31-33. doi:[10.1080/08035320600649473](https://doi.org/10.1080/08035320600649473)
3. Lotan D, Yoskovitz G, Bisceglia L, Gerad L, Reznik-Wolf H, Pras E. A combined approach to the molecular analysis of cystinuria: from urinalysis to sequencing via genotyping. *Isr Med Assoc J.* 2007;9(7):513-516.
4. Benoist JF, Imbard A, Dreux S, et al. Antenatal biochemical expression of cystinuria and relation to fetal hyperechogenic colon. *Clin Chem.* 2007;53(1):149-150. doi:[10.1373/clinchem.2007.080705](https://doi.org/10.1373/clinchem.2007.080705)
5. Vena F, Mazza A, Bartolone M, et al. Hyperechogenic fetal bowel: Current evidence-based prenatal diagnosis and management. *J Clin Ultrasound.* 2023;51(7):1172-1178. doi:[10.1002/jcu.23528](https://doi.org/10.1002/jcu.23528)
6. Hurt L, Wright M, Dunstan F, et al. Prevalence of defined ultrasound findings of unknown significance at the second trimester fetal anomaly scan and their association with adverse pregnancy outcomes: the Welsh study of mothers and babies population-based cohort. *Prenat Diagn.* 2016;36(1):40-48. doi:[10.1002/pd.4708](https://doi.org/10.1002/pd.4708)
7. Paulson EK, Hertzberg BS. Hyperechoic meconium in the third trimester fetus: an uncommon normal variant. *J Ultrasound Med.* 1991;10(12):677-680. doi:[10.7863/jum.1991.10.12.677](https://doi.org/10.7863/jum.1991.10.12.677)
8. Fung AS, Wilson S, Toi A, Johnson JA. Echogenic colonic meconium in the third trimester: a normal sonographic finding. *J Ultrasound Med.* 1992;11(12):676-678. doi:[10.7863/jum.1992.11.12.676](https://doi.org/10.7863/jum.1992.11.12.676)
9. Brasseur-Daudruy M, Garel C, Brossard V, Broux F, Heckettweiler B, Eurin D. Hyperechogenic colon: a prenatal sign of cystinuria?. *Prenat Diagn.* 2006;26(13):1254-1255. doi:[10.1002/pd.1597](https://doi.org/10.1002/pd.1597)